

# Extracorporeal Acoustic Wave Therapy and Multiple Symmetric Lipomatosis

Carlotta Scarpa, MD, PhD  
Vincenzo Vindigni, MD, PhD  
Franco Bassetto, MD

**Summary:** Acoustic waves are mechanical waves recently used to activate tissue metabolism by exploiting the cell permeabilization caused by their passage. We report a case of a retroauricular lipoma in a 44-year-old woman affected by multiple symmetric lipomatosis and treated with extracorporeal acoustic wave therapy. The adipose thickness of the lipoma was reduced from 35.8 to 21mm, with increased softness at palpatory examination. (*Plast Reconstr Surg Glob Open* 2015;3:e430; doi: 10.1097/GOX.0000000000000407; Published online 22 June 2015.)

First applied in the 1980s in Germany as an electrohydraulic generator and quickly developed in the last 60 years for orthopedic, physiatric, and urological purposes, extracorporeal acoustic wave therapy (EAWT) is now applied by electromagnetic supply of mechanical waves, which, unlike ultrasound technology, are characterized by short length (<10  $\mu$ s), high peak pressure (>100 MPa), rapid rise in pressure, and a frequency spectrum between 16 Hz and 20 MHz.<sup>1,2</sup>

These waves are capable of crossing gases, solids, and liquids, and thanks to their mechanism of action that allows them to expand at a speed greater than that of sound, their propagation disturbs and changes intramolecular bonds. The change in fluid pressure leads to a cavitation effect, with microdamage to tissues, especially visible at the point on which the waves are focused. At present, the possibility of changing the wave focus has led to better control of the destructive cavitation effect and to the use of EAWT to activate tissue metabolism. As hypothesized, wave passage through tissues, such as skin, extracellular matrix, vessels, adipose tissues, and inflammatory cells, leads to neoangiogen-

esis, vasodilation, stimulation of proliferation, release of growth factors, and anti-inflammatory effects.<sup>3,4</sup>

The recent creation of a new handpiece, based on defocused supply of the acoustic wave, now allows superficial treatment of, for example, subcutaneous adipose tissue deposits, by exploiting 2 effects<sup>5-8</sup>: (1) mechanical effect, because of increased cell permeability, with consequent enzymatic (lipase) demolition of fats and cellular lysis (reduction of adipose thickness) and (2) stimulated production of new collagen and elastin fibers, together with activation of hematic and lymphatic systems (dermoepidermal strengthening).

In light of these premises, we treated a retroauricular lipoma in a patient affected by multiple symmetric lipomatosis,<sup>9,10</sup> a rare disease of unknown etiology with an incidence of 1:25,000, more frequent in adult males, often associated with alcohol abuse and other diseases, such as diabetes, somatic and autonomic neuropathy, and clinically characterized by the presence of multiple, symmetrical, noncapsulated lipomas, mostly in the neck and upper trunk. Histologically, the deposits are not capsulated and are represented by small adipocytes, with a slight increase in vascular and fibrous elements, and infiltration across the fasciomuscular and vasculonervous planes.

*From the Clinic of Plastic and Reconstructive Surgery, University of Padova, Padova, Italy.*

*Received for publication November 20, 2014; accepted May 4, 2015.*

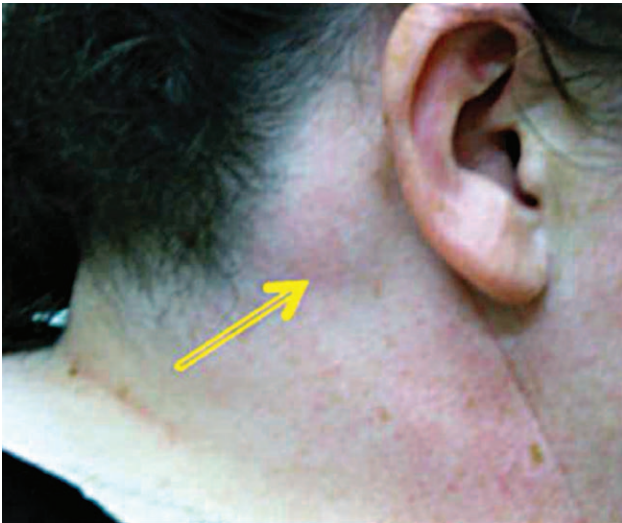*Copyright © 2015 The Authors. Published by Wolters Kluwer Health, Inc. on behalf of The American Society of Plastic Surgeons. All rights reserved. This is an open-access article distributed under the terms of the Creative Commons Attribution-NonCommercial-NoDerivatives 3.0 License, where it is permissible to download and share the work provided it is properly cited. The work cannot be changed in any way or used commercially.*

DOI: 10.1097/GOX.0000000000000407

## CASE REPORT

A 44-year-old woman, surgically treated several times for multiple symmetric lipomatosis, presented

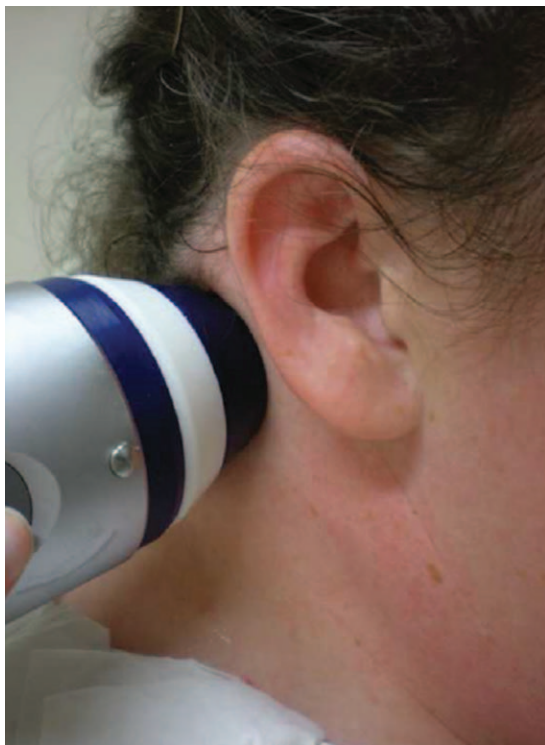**Disclosures:** Dr. Scarpa and Prof. Bassetto have received personal fees for expert testimony and speakers bureaus. Dr. Vindigni does not have financial support from Storz Medical. The Article Processing Charge was paid for by the authors.



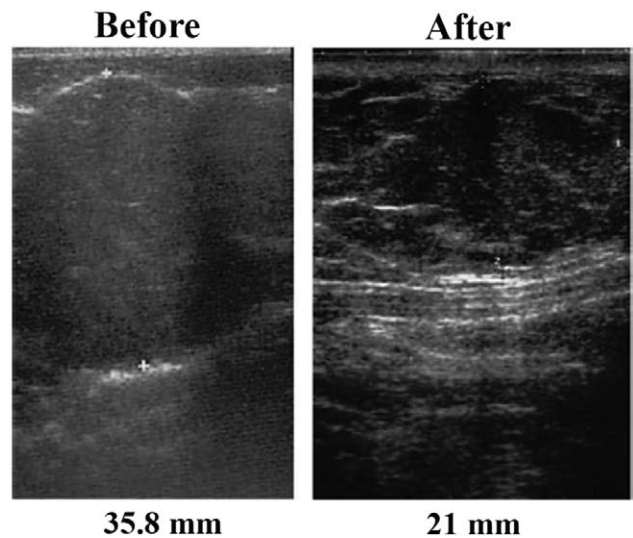
**Fig. 1.** Retroauricular lipoma.

a retroauricular lipoma (Fig. 1). She reported pain and limited sleep, because of the inability to rest her head on the pillow. Clinically, the lipoma was hard, fibrotic, and 35.8-mm thick, as confirmed by ultrasound (Fig. 3A).

After informed consent, the lipoma was treated with EAWT (Cellactor SC1, Storz Medical, Switzerland) applying only the defocused planar handpiece once a week, for a total of 8 sessions (Fig. 2). The energy range was 0.09–0.27 mJ/mm<sup>2</sup>, with a conse-



**Fig. 2.** Treatment with defocused EAWT.



**Fig. 3.** Ultrasound examination of adipose thickness: (A) pretreatment and (B) posttreatment at 1 month.

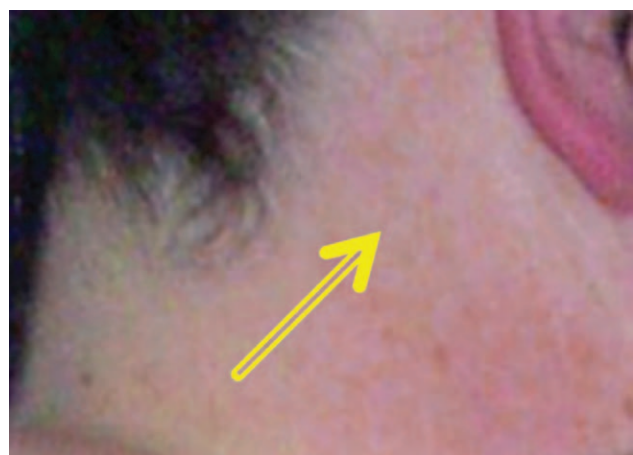
quent frequency of 5–3 Hz and a total number of pulses of 1200 per session.

### RESULTS

One month after the end of treatment, a further ultrasound scan was taken to check adipose thickness, which had been reduced from 35.8 to 21 mm (Figs. 3, 4), clinically evident as increased softness at palpation. The patient reported less pain and increased hours of sleep. The treatment was well accepted by the patient, because of the absence of anesthesia, pain and scarring, noninvasivity, and feasibility in a medical office.

### CONCLUSIONS

EAWT is a noninvasive treatment, painless, and well accepted by patients. In view of its features and the results obtained, it may be a good alternative or adequate



**Fig. 4.** Posttreatment picture at 1 month.

support to traditional treatment in patients affected by diseases requiring multisession surgical therapy.

**Carlotta Scarpa, MD, PhD**

Clinic of Plastic and Reconstructive Surgery  
University of Padova  
Via Giustiniani 2  
35100 Padova, Italy  
E-mail: carlotsc@tin.it

#### REFERENCES

1. Wilbert DM. A comparative review of extracorporeal shock wave generation. *BJU Int.* 2002;90:507–511.
2. Wess O. Physics and technology of shock wave and pressure wave therapy. *ISMST Newsletter.* 2006; 2: 2–12.
3. Mariotto S, de Prati AC, Cavalieri E, et al. Extracorporeal shock wave therapy in inflammatory diseases: molecular mechanism that triggers anti-inflammatory action. *Curr Med Chem.* 2009;16:2366–2372.
4. Mittermayr M, Antonic V, Hartinger J, et al. Extracorporeal shock wave therapy (ESWT) for wound healing: technology, mechanism, and clinical efficacy. *Wound Repair Regen.* 2012;20:456–465.
5. Gambihler S, Delius M, Ellwart JW. Permeabilization of the plasma membrane of L1210 mouse leukemia cells using lithotripter shock waves. *J Membr Biol.* 1994;141: 267–275.
6. Kodama T, Hamblin MR, Doukas AG. Cytoplasmic molecular delivery with shock waves: importance of impulse. *Biophys J.* 2000;79:1821–1832.
7. Koshiyama K, Kodama T, Yano T, et al. Structural change in lipid bilayers and water penetration induced by shock waves: molecular dynamics simulations. *Biophys J.* 2006;91: 2198–2205.
8. Angehrn F, Kuhn C, Voss A. Can cellulite be treated with low-energy extracorporeal shock wave therapy? *Clin Interv Aging.* 2007;2:623–630.
9. Busetto L. Multiple symmetric lipomatosis. In: Lang F, ed. *Encyclopedia of Molecular Mechanisms of Disease.* Berlin, Heidelberg: Springer-Verlag GmbH; 2009:1375–1377.
10. Enzi G, Busetto L, Ceschin E, et al. Multiple symmetric lipomatosis: clinical aspects and outcome in a long term longitudinal study. *Int J Obes.* 2002; 26:253–261